UNDER PEER REVIEW

Case study

An Impacted Denture in the Hypopharynx-A quick intervention reduces morbidity

ABSTRACT

A 32yrs old male police officer was brought to A & E on account of ingestion of an denture,while trying to to drink his medications,about 4hours prior to presentation in our facilities.He had immediate painful distress, choking sensation cough and with mild difficulty in breathing.Plain radiogragh showed opacification with increased prevertebral soft tissue shadow in the region of C4-C5 of the hyphopharynx.He had emergency examination under general anaesthesia and the foreign body was extracted from the throat. Immediate post operative condition was satisfactory.we present this case to show the importance of the use of a well anchored artificial denture as well as to exercise caution when taking medications by people with artificial denture.Also earlier presentation and quick intervention as done in this case prevent serious morbidity that can be associated with such condition.

Keywords:Denture,Hypopharynx,Foreign body impaction

Introduction

Foreign body ingestion and aspiration is among the most common causes of emergency department visit associated with high morbidity and mortality[1]. Coins, meat bone, marbles, safety pins, button,batteries and screws are among the most common ingested and aspirated foreign bodies in pediatric age group[2]. In adults, coins and denture has been reported to be the most common aspirated foreign bodies. Sharp foreign body aspirations and injections is frequently associated with serious complications. If they are not removed at the earliest, they can cause esophageal erosion, perforation, abscess or medias tinitis[3]. Early removal of this

UNDER PEER REVIEW

foreign body must be considered to reduce the risk of complication of dislodgement and subsequent ingestion or aspiration of dental appliances is not a common condition. An accidental ingestion of an appliance can create a medical or a surgical emergency that can lead to serious complications, including death from aspiration of the foreign body[4]. Because of their sizes, rigidity and pointed edges; dentures get frequently impacted in the oesophagus and are difficult to retrieve endoscopically[5].

The tooth contributes to the esthetic appearance of the face. Biographers and playwrights, among others, in portraying the facial appearance of their characters, have employed this feature. While in the past early European visitors to Nigeria admired her natives "perfect row of whiteteeth," the converse is true now as a result of tooth loss due to caries and periodontal disease. This situation has led to an increase in the number of people wearing dentures in our environment and, thus, a proportionate increase in the incidence of esophageal impacted dentures[6].

Case Report

A 32yrs old male who was brought to our A & E on account of ingestion of a denture about 4hours prior to presentation. He was apparently well until fours prior to presentation when he accidentally swallowed the denture in his upper teeth while taking his medications. He had immediate painful distress, choking sensation,cough and mild difficulty in breathing. No nasal or otological symptoms. No previous history of similar ingestion. He claimed to be conversant with routine daily removal and cleaning of the denture without any issue. No history of hypertension, diabetes, Peptic ulcer, asthma, and surgery in the past. Examination revealed a young man fully consciuos and well oriented but in painful distress.He not pale, anicteric, af ebile(36.8), and not dehydrated. PR :74bpm, BP 150/90mmHg, SPO2:97% on room air and RR: 28cpm. Ear & Nose examination revealed no abnormality, Oral cavity &

UNDER PEER REVIEW

oropharynx revealed good oral hygiene with abscence of 2 upper incisors and left canine, no hyperemia or swelling. No neck swelling and his chest was clinically clear.

Plain radiograph of soft tissue neck done revealed opacification with increased prevertebral soft tissue shadow in the region of C4-C5 of the hyphopharynx (Fig 1).He had emergency examination under general anaesthesia and endoscopy. The denture (Fig 2) was found impacted in hypopharynx covered by caked blood. It was extracted with a grasping forceps with little resistance.

The immediate post operative condition was satisfactory. Patient tolerated graded oral feeding after 24 hours post operative time and was subsequently discharged 48 hours post operative time.

Discussion

Impaction of dentures in the esophagus is not rare in Nigeria. Most patients are aware of the diagnosis before seeking treatment. Exceptions to this are children, the mentally handicapped, and those under the influence of alcohol. In addition, acrylic dentures are associated with reduced sensitivity of the oral cavity because of the insulating nature of the resins used in their fabrication[6].Though coins are the commonest foreign bodies which are seen in the oesophagus in children, dentures are common in aged people due to the decreased sensation of the oral cavity in denture wearers and the poor motor control of the laryngopharynx[7].

Swallowing and aspiration of dental foreign objects is often reported in the literature.Swallowing

UNDER PEER REVIEW

is more common than aspiration and usually seen in the elderly.As predicted by Okeowo and Okafor and noted by Nwafo et al,artificial denture use has increased among Nigerians. In previous studies from Lagos and Enugu, impacted dentures among Nigerians constituted 4.9% and 2.2%, respectively, of foreign bodies in the pharynx and esophagus[7]. A radiological imaging can determine the exact site of the radio-opaque impacted foreign body. Dentures, however, are frequently made of acrylic resin, which is a radiolucent material and thus, they are difficult to assess on plain X-Rays, though the radio-opaque wire hooks of the dentures can sometimes be seen, if they are present[4]. It is difficult to localize the site of impacted denture by imaging technique if there is no wire in it unless there is complications such as emphysema, mediastinitis, increased prevertebral shadow and loss of cervical lordosis. Their radiolucency makes radiological localization almost impossible, and because of their rigidity, large size, irregular and unyielding edges,impacted dentures are apt to produce lacerations during endoscopic removal from gullets rendered friable by impaction [8].Most of the swallowed foreign bodies are impacted at the cervical and the upper oesophagus .In our index case it was embedded in the hypopharynx thereby causing mild respiratory difficulty. Moreso, there is a high risk of aspiration of the blood emanating from injury to the hypopharyngeal structures by the sharp edges of the denture.This made urgent intervention necessary.

Few reports have described the usefulness of an endoscopic removal, even for sharp or penetrating foreign bodies[9]. However, the sharp hooks of the dentures are likely to damage the oesophageal or the pharyngeal wall. Consequently, it is difficult to remove the dentures endoscopically. Many articles have supported this primarily surgical approach over an endoscopic removal for sharp dentures..

Endoscopic extraction of dentures carries a high risk of perforation[10].Factors responsible for this

UNDER PEER REVIEW

include the size, rigidity, sharp edges of the dentures,and attempting extraction in less-than-ideal situations. In addition to these, the degree of periesophagitis at the site of impaction may increase the risk of perforation. Endoscopy was done is this case as the radiograph had already given a guide as to where the denture was impacted and such location may not carry much morbidity with quick intervention.

Conclusion

Impacted denture exctraction via rigid endoscopy carry a high risk of perforation, though it can be undertaken under direct vision and in an ideal situation with judicious use of the Shears forceps. There is no room for expectant or conservative management in cases of impacted dentures, as the risk of complications increase the longer it takes before appropriate surgical intervention.4'10"2 It then becomes imperative for the denture to be removed under direct vision as soon as a diagnosis is made.

References

1. Shivakumar AM, Naik AS, Prashanth KB, Yogesh BS, Hongal GF. Foreign body in upper digestive tract. *Indian J Pediatr*. 2004;**71**(8):689-93.

2. Wani N, Ganie FA, Lone H, Wani ML, Ahangar AG, Lone GL, et al. The Pattern, Presentation and Management of Pardah Pin Inhalation: Report from a Single Center in Northern India. *Bull Emerge Trauma*. 2013;**1**(4):171-4.

3. Güitrón A, Adalid R, Huerta F, Macías M, Sánchez-Navarrete M,Nares J. Extraction of foreign bodies in the esophagus: Experience in 215 cases. *Rev Gastroenterol Mex*. 1996;**61**(1):19-26.

4.Neeraj S Rohida, Wasundhara A Bhad. Accidental ingestion of a fractured Twin-block appliance. *Am J Orthod Dentofacial Orthop.* 2011;139:123-25.

UNDER PEER REVIEW

5. Dalvi AN, Thapar VK, Jagtap S, Barve DJ, Savarkar DP, Garle MN, et al. Thoracoscopic removal of impacted denture: Report of a case with review of literature. *J Min Access Surg.* 2010 Oct-Dec; 6: 119-21.

6. Nwaorgu OG, Onakoya PA, Sogebi OA, Kokong DD, Dosumu OO. Esophageal impacted dentures. *J Natl Med Assoc*. 2004;**96**(10):1350-3.

7.Toshima T, Morita M, Sadanaga N, Yoshida R, Yoshinaga K, Saeki H, et al. Surgical Removal of a Denture with Sharp Clasps Impacted in the Cervicothoracic Esophagus: Report of Three Cases. *Surg Today.* 2011; 41:1275–79.

8. Khan MA, Hameed A, Choudhry AJ.Management of foreign bodies in the esophagus. *J Coll Physicians Surg Pak*. 2004;**14**(4):218-20.

9. Rathore PK, Raj A, Sayal A, Meher R, Gupta B, Girhotra M. Prolonged foreign body impaction in the oesophagus. *Singapore Med J.* 2009; 50(2) : e53-54.

10. Nwafo DC, Anyanwu CH, Egbue MO. Impacted esophageal foreign bodies of dental origin. Ann Otol Rhinol Laryngol. 1980:89:129-131.

Figure legends

Fig 1:Lateral view of plain radiograph of soft tissue neck showing opacification with increased prevertebral soft tissue shadow in the region of C4-C5 of the hyphopharynx

UNDER PEER REVIEW
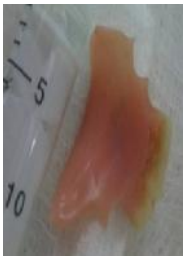
Fig 2:The Acrylic Denture