UNDER PEER REVIEW

Case Study

Urinary bladder rupture after a long party-night

.

ABSTRACT

Introduction:

Urinary bladder rupture is a rare life-threatening event . Especially patients with alcohol intoxication are unable to provide a clear history and present are unclear abdominal pain. Under these circumstances the diagnosis of a urinary bladder rupture requires a high index of suspicion

Presentation of Case:

After a long party night with consumption of alcohol a 42-years old man wakes up with severe abdominal pain. Physical examination shows peritonitis- signs especially in the lower abdominal part. Ultrasound detects free intraperitoneal fluid. The CT scan of the Abdomen shows perihepatic fluid. By acute abdomen without any signs of perforation we performed a laparotomy. Intraoperatively a 3x2 cm rupture of the superior wall is seen and closed with sutures. After the operation the patient is received to the ICU.

Discusccion:

Urinary blader rupture has a high mortality often due to late diagnosis. Spontaneous rupture of the urinary bladder is often associated with malignant disease, bladder outflow obstruction and neurogenic bladder. Alocohol-intaoxicated patients are challenging cases in the emergency room. A clear history of the disease is not presented. In our case the patient had non traumatic event or any urological diseases. So it is possible like reported in a few earlier cases that urinary retention in these cases may be due to rapid filling of the bladder secondary to the diuretic effect of alcohol. Moreover, nausea and vomiting might lead to enhanced intra-abdominal pressure and higher probability of spontaneous bladder rupture

Conclusion:

Spontaneous rupture of the urinary bladder is a rare cause for acute abdominal pain with a high mortality because of delayed diagnosis. Especially Alcohol-intoxicated patients are not able to present any history of the disease. More over a urinary bladder rupture should be considered by patients with alcohol intoxication and without any traumatic event or known urological diseases like it is presented in our case.

Keywords: [Put four to eight keywords } (Arial, inclined, 10 font, justified)

1. INTRODUCTION

Urinary bladder rupture is a rare life-threatening event (1). Especially patients with alcohol intoxication are unable to provide a clear history and present are unclear abdominal pain. Under these circumstances the diagnosis of a urinary bladder rupture requires a high index of suspicion (2).

UNDER PEER REVIEW

2. PRESENTATION OF CASE

After a long party night with consumption of alcohol a 42-years old man wakes up with severe abdominal pain. Physical examination shows peritonitis- signs especially in the lower abdominal part. Ultrasound detects free intraperitoneal fluid. The CT scan of the Abdomen shows perihepatic fluid. By acute abdomen without any signs of perforation we performed a laparotomy. Preoperatively an indwelling catheter is inserted into the patient's bladder via the urethra and a macrohematuria occurs. Intraoperatively a 3x2 cm rupture of the superior wall is seen and closed with sutures. After the operation the patient is received to the ICU. The drunken patient could not remember any traumatic event which causes the rupture.

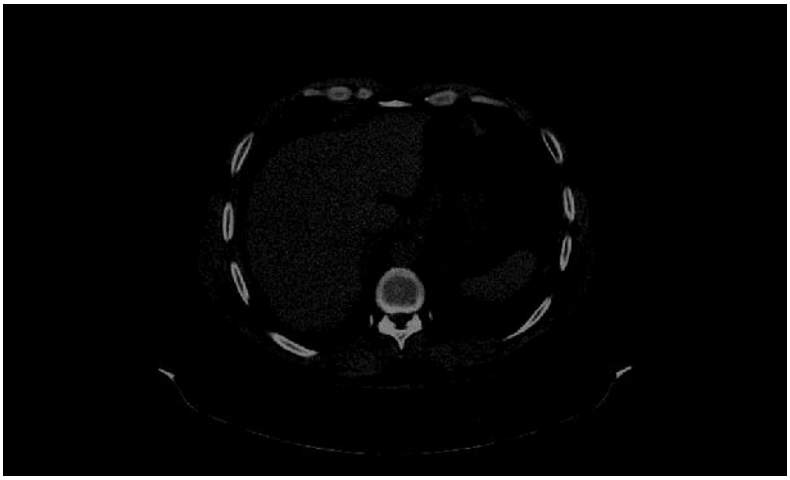

3. DISCUSSION

Urinary blader rupture has a high mortality (47%) often due to late diagnosis (3). Spontaneous rupture of the urinary bladder is often associated with malignant disease, bladder outflow obstruction and neurogenic bladder (4, 5). Alocohol-intaoxicated patients are often challenging cases in the emergency room. A clear history of the disease is not presented. In our case the patient had non traumatic event or any urological diseases. It is possible like reported in a few earlier cases that urinary retention in these cases may be due to rapid filling of the bladder secondary to the diuretic effect of alcohol. The distention of the urinary bladder may lead to an atonic decompensated bladder which becomes stretched and thinner. As the dome of the urinary bladder is the weakest point within the bladder wall, over-distension and thinning of the dome eventually lead to bladder rupture. Moreover, nausea and vomiting might lead to enhanced intra-abdominal pressure and higher probability of spontaneous bladder rupture (6).

4. CONCLUSION

Spontaneous rupture of the urinary bladder is a rare cause for acute abdominal pain with a high mortality because of delayed diagnosis. Especially Alcohol-intoxicated patients are not able to present any history of the disease. More over a urinary bladder rupture should be considered by patients with alcohol intoxication and without an traumatic event or known urological diseases like it is presented in our case.

UNDER PEER REVIEW

CONSENT (WHERE EVER APPLICABLE)

"All authors declare that 'written informed consent was obtained from the patient (or other approved parties) for publication of this case report and accompanying images. A copy of the written consent is available for review by the Editorial office/Chief Editor/Editorial Board members of this journal."

REFERENCES

1. Festini G, Gregorutti S, Reina G, Bellis GB. Isolated intraperitoneal bladder rupture in patients with alcohol intoxication and minor abdominal trauma. Annals of emergency medicine. 1991;20(12):1371-2.
2. Daignault MC, Saul T, Lewiss RE. Bedside ultrasound diagnosis of atraumatic bladder rupture in an alcohol-intoxicated patient: a case report. Critical ultrasound journal. 2012;4(1):9.
3. Hansen HJ, Eldrup J. Spontaneous rupture of the urinary bladder--a late complication to radiotherapy. Case report. Scandinavian journal of urology and nephrology. 1989;23(4):309-10.
4. Abu Mahfouz I, Sayer T, Phillips C. Conservative management of spontaneous rupture of the urinary bladder. International urogynecology journal. 2011;22(5):629-31.
5. Haddad FS, Pense S, Christenson S. Spontaneous intraperitoneal rupture of the bladder. Le Journal medical libanais The Lebanese medical journal. 1994;42(3):149-54.
6. Muneer M, Abdelrahman H, El-Menyar A, Zarour A, Awad A, Al-Thani H. Spontaneous Atraumatic Urinary Bladder Rupture Secondary to Alcohol Intoxication: A Case Report and Review of Literature. The American journal of case reports. 2015;16:778-81.