UNDER PEER REVIEW

Original Research Article

The efficacy of intravenous immunoglobulin in the treatment of patients with acute disseminated encephalomyelitis

Abstract.

Acute disseminated encephalomyelitis (ADEM) is a monophase process nevertheless sometimes aggravated by relapses (so-called multiphase course of the disease). In such case the treatment must be targeted at reducing clinical manifestations of the disease and prevention of its relapses. The aim of our work was to analyze efficacy of intravenous immunoglobulin as therapeutic option in the treatment of patients with ADEM.

Therapeutic efficacy of intravenous imsssmunoglobulin has been analyzed in the treatment of 27 patients with ADEM: 12 men and 15 women aged 17 – 53 (average index 31.7±1.6). The patients were daily administered intravenous immunoglobulin – 0.4 mg per 1 kg of body mass in 200 ml of isotonic sodium chloride solution (within 5 days). The treatment was followed by monthly administration of immunoglobulin – 0.4 mg per 1 kg of body mass in 200 ml of isotonic sodium chloride solution (within 24 months). The control group included 20 patients aged 19 – 51 (average index 36±3) with the same demographic characteristics whose treatment did not include intravenous immunoglobulin.

The investigation has proved positive therapeutic efficacy of intravenous immunoglobulin in the treatment of patients with ADEM – reduction of clinical manifestations of the disease, in particular a decrease in neurological deficit level. Monthly intravenous immunoglobulin administration also has great prognostic significance in prevention relapses of the disease (multiphase ADEM course).

Key worlds: acute disseminated encephalomyelitis, treatment, intravenous immunoglobulin

1. Introduction:

Increasing the efficacy of the treatment of patients with acute disseminated encephalomyelitis (ADEM) remains an actual problem for clinical neurology.

ADEM is an autoimmune disease characterized by presence of inflammation (demyelination) foci, having been caused by infectious disease or vaccination, in the central nervous system [1]. Relapses of acute disseminated encephalomyelitis are called multiphase course of the disease [2, 3]. Therefore treatment of acute disseminated encephalomyelitis must be aimed at reducing intensity of clinical symptoms and prevention of the disease relapses.

In case of ADEM demyelination foci occur due to sensitization of lymphocytes to the brain tissues leading to the inflammatory response against antigens of the brain

UNDER PEER REVIEW

[4, 5, 6, 7, 8]. As far as development of the disease is caused by autoimmune response, patients are recommended pathogenetic immunosuppressive therapy aimed at suppression of the immune response to infectious agent or vaccination with the high doses of corticosteroids [9, 10, 11, 12, 13]. Hormone therapy is also recommended due to its ability to block or modify the course of experimental allergic encephalomyelitis. In addition to its anti-inflammatory and immunosuppressive action, hormone therapy restores the function of blood-brain barrier, activates phagocytosis and immunoglobulin synthesis. Intravenous administration of corticosteroids over a period of several days followed by their peroral administration is considered to be the most common treatment scheme [14, 15, 16, 17].

However, in cases when the efficacy of pulse-therapy with corticosteroids is insufficient, intravenous administration of immunoglobulin is used [18, 19, 20, 21, 22, 23, 24].

Immunobiological action of immunoglobulin is provided due to the presence of antibodies against various infectious agents (virus of measles, influenza, varicella, parotitis, poliomyelitis, rubella, herpes-associated group, hepatitis A and B, pneumococcus). Immunoglobulin also has immunomodulating effect on cellular and humoral factors: blockade of Fc-receptors of autoantibodies, influence on the complement system, cytokines, modulation of T and B cells activation and differentiation [25, 26, 27, 28, 29, 30, 31, 32].

Experimental data show that in case of inflammatory diseases immunoglobulin may influence on the local immune response in the central nervous system, regulating nitric oxide release and microglia function [127]. Immunoglobulin administration provides supply of specific antibodies with a wide range of antigen and antibody specificity, binding and neutralizing pathogens as well as inhibiting production of autoantibodies. Remyelination stimulation can be a possible consequence of immunoglobulin use [33, 34].

Plasmapheresis method is also used for the treatment of patients with the diagnosis of ADEM that is proved by the results of multiple investigations [35, 36, 37, 38, 39].

The **aim** of our work was to analyze the efficacy of intravenous immunoglobulin as therapeutic option in the treatment of patients with ADEM.

Methods: Therapeutic efficacy of intravenous immunoglobulin has been analyzed in the treatment of 27 patients with ADEM: 12 men and 15 women aged 17 – 53 (average index 31.7±1.6). Influence of the treatment on changes in neurological status of patients as well as variations in the disease course have been studied.

The patients were separated into two groups depending on the treatment method. The first (main) group included 27 patients who were daily administrated intravenous immunoglobulin in the dose of 0.4 mg per 1 kg of mass of body in 200

ml of isotonic sodium chloride solution (within 5 days). The treatment was followed by monthly administration of human normal immunoglobulin – 0.4 mg per1 kg of body mass in 200 ml of isotonic sodium chloride solution (within 12 months) as a method of ADEM monotherapy. The control group included 20 patients aged 19 – 51 (average index 36 ± 3) with the same demographic characteristics. Intravenous administration of human normal immunoglobulin was not used in the treatment of control group patients.

According to indications, in some cases the treatment was preceded by premedication with hormonal pulse-therapy, using methylprednisolone in the dose of 500-1000 mg daily in 200 ml of isotonic sodium chloride solution (within 5 days).

Therapeutic efficacy of the performed treatment of patients with ADEM has been assessed by the amount of restored neurological functions (in points), using the Kurztke – Expanded Disability Status Score (EDSS) scale [40] and by the number of demyelination disease relapses over a 12-month period of observation. The decrease of neurological disorders index by 1.5-2 points according to EDSS scale was considered a significant improvement, the decrease by 1 point – a moderate improvement, the decreased by 0.5 point – an insignificant one. The absence of restored neurological functions according to the EDSS scale was assessed as an absence of therapeutic effect.

Results:

The analysis of pre-treatment clinical and neurological examination data shows that disability level at baseline (in points) was the same in both clinical groups (Table 1). The disability of patients according to the EDSS scale mostly had mild and moderate level, much less frequently – severe one.

The use of immunomodulating method – human normal immunoglobulin for intravenous administration – in the treatment of the patients with ADEM had the positive influence on restoring the neurological functions and reducing the disability level in the EDSS points. It has been confirmed by the results of therapy of patients of the main and control groups (their average disability indices are given in Table 2 and Figs 1 and 2).

Table 1. The disability baseline level in patients with ADEM of different clinical groups.

Clinical group of patients with ADEM	Disability level according to the EDSS scale, points		
	mild (1.0-3.5)	moderate (4.0-6.0)	severe (6.5-9.0)
main (n = 27)	n = 16 (3 ± 0.1)	n = 10 (4.8±0.2)	n = 1 (6.5)
control (n = 20)	n = 12 (3.1 ± 0.1)	n = 8 (4.3±0.2)	–

Note. In brackets – average index of the total number of patients.

Table 2. Dynamics of average index of disability in patients with ADEM of different clinical groups according to the EDSS scale after the treatment (M±m).

Clinical group of patients with ADE	Results of therapy	Disability level according to the EDSS scale, points	
		Before treatment	After treatment
Main (n=27)	significant improvement (n=2)	3.5	2
	moderate improvement (n=13)	4.0±0.3	3.0±0.3*
	insignificant improvement (n=9)	4.2±0.5	3.7±0.5
	no improvement (n=3)	3.3±0.5	3.3±0.5
Control (n=20)	moderate improvement (n=6)	4.7±0.2	3.7±0.2*
	insignificant improvement (n=8)	3.6±0.3	3.1±0.3
	no improvement (n=6)	3.3±0.4	3.3±0.4

Note. *– reliability of difference between the indices before and after the treatment, $p<0.05$.

The data in Table 2 show that among the patients of the main group who were administered intravenous immunoglobulin, significant and moderate improvement was observed in 55.6% of patients, significant improvement was observed in two patients (7.4%) and 13 patients (48.2%) showed persistent moderate improvement of neurological functions: increase of strength in paretic extremities, reduction of the increased muscle tone, decrease of expressed static and dynamic ataxia, improvement (or normalization) of urination function. The decrease of the average indices of disability according to the EDSS scale from 4±0.3 to 3±0.3 points ($p<0.05$) was observed. 9 patients (33.3%) showed a mild clinical improvement: reduction of neurological deficit according to the EDSS scale from 4.2±0.5 to 3.7±0.5 points ($p>0.05$). 3 patients of the main group (11.1%) did not demonstrate any significant changes in the neurological status.

The efficacy of treatment of the patients in the control group with the use of traditional methods (vascular-metabolic therapy) was significantly lower: moderate improvement was observed in 6 patients (30%), mild improvement – in 8 patients (40%), the effect was absent in 6 patients (30%).

The results of neurological examination of patients over a 24-month period are shown in Table 3 and Fig. 3. After the treatment patients of both groups demonstrated the decrease of neurological deficit, measured according to the EDSS scale, compared to the indices before treatment ($p<0.01$). The patients of the main group

showed some decrease of neurological deficit 12 months after leaving the hospital ($p>0.05$); the patients of the control group on the contrary showed the increase of neurologic deficit, yet not confirmed statistically ($p>0.05$). During the second examination after 12 months (24 months after beginning of the treatment) even more significant reduction of the level of neurological disorders of the patients of the main group ($p<0.05$) and its increase in the patients of the control group ($p<0.05$) was observed, which is explained by development of demyelination disease relapses over a 24-month observation period.

Table 3. Dynamics of changes in neurological status of patients with ADEM over a 24-month observation period.

Group of patients	Disability level according to the EDSS scale, points			
	Before treatment	After treatment	After 12 months	After 24 months
main (n=27)	3.8±0.2	3.0±0.2	2.8±0.3	2.3±0.4
control (n=20)	3.9±0.2	3.4±0.2	3.8±0.3*	4.1±0.3^

Note. *– reliability of difference between the indices of the main and control groups,

$p<0.05$; ^ – $p<0.001$.

As can be seen from the Table 3, six and twelve months after beginning of the treatment, the patients of the control group demonstrated the increase of neurological deficit compared to the patients of the main group.

Over a 24-month observation period, the patients of the main group had 2 relapses of disseminated encephalomyelitis, the patients of the control group – 7 relapses (one woman had two relapses over the year) (Table 4).

Table 4. Frequency of relapses in the patients with ADEM over a 24-month observation period.

Clinical group of patients with ADEM	Observation period					
	1 month	6 months	12 months	18 months	24 months	Total number of relapses
main (n=27)	–	1	1	–	–	2
control (n=20)	–	1	2	2	2	7

To illustrate the clinical efficacy of human normal immunoglobulin several clinical observations are given below.

Observation No. 1. Patient K. (woman) was being treated at the neurological department of the Alexandrovskaya City Clinical Hospital with a diagnosis of acute disseminated encephalomyelitis. According to the neurological examination, the patient had problems with movement of right eyeball outwards, animation of deep reflexes with anisoreflexia (S>D), decrease of abdominal reflexes, swaying when performing the Romberg test as well as reduction of vibration sensitivity on bony prominences of hands and feet to 9-10 seconds. MRI investigation showed the signs of disseminated demyelination process in the brain (multiple foci of hyperintensive signal on T2-weighted image without clear contours (up to 12 mm in diameter) were seen in the white matter of the cerebral hemispheres supratentorially and periventricularly, in the brainstem, cerebellum, right ophthalmic nerve). After the pulse-therapy with glucocorticoids, the patient was daily administered human normal immunoglobulin intravenously in the dose of 0.4 mg per kg (within 5 days). The positive dynamics of clinical symptoms was recorded 7 days after beginning of the treatment (movements of right eyeball outwards became more frequent, tendon anisoreflexia reduced). The treatment was followed by monthly administration of human normal immunoglobulin in the dose of 0.4 mg/kg. No relapses were observed over 12 months of observation. The patient felt good, without future hospitalization.

Observation No. 2. Patient G. (woman) was being treated at the neurological department of the Kyiv City Clinical Hospital № 4 with a diagnosis of acute disseminated encephalomyelitis. According to the neurological examination, the patient had weak convergence of eyeballs, asymmetry of face, tongue deviation to the right, positive subcortical reflexes, increase of deep reflexes with anisoreflexia (S>D), reduction of abdominal reflexes, swaying when performing the Romberg test. MRI investigation showed the signs of disseminated demyelination process in the brain (multiple foci of hyperintensive signal on T2-weighted image without clear contours with the perifocal edema (up to 10-12 mm in diameter) were seen in the white and gray matter of the cerebral hemispheres in the frontal and parietal lobes subcortically). After the pulse therapy with glucocorticoids, the patient was daily administered human normal immunoglobulin intravenously in the dose of 0.4 mg/kg (within 5 days). The positive dynamics of clinical symptoms was recorded 8 days after beginning of the treatment (tendon anisoreflexia and swaying reduced). The treatment was followed by monthly administration of human normal immunoglobulin in the dose of 0.4 mg/kg. Three and nine months after beginning of the treatment the patient had two more MRI investigations of the brain that showed positive dynamics of the disease: reduction of demyelination foci and no accumulation of contrast agents (Figs. 5 and 6). No relapses were observed over 12 months of observation.

Fig. 1. Dynamics of restoring neurological functions of patients with ADEM in different clinical groups as a result of treatment.

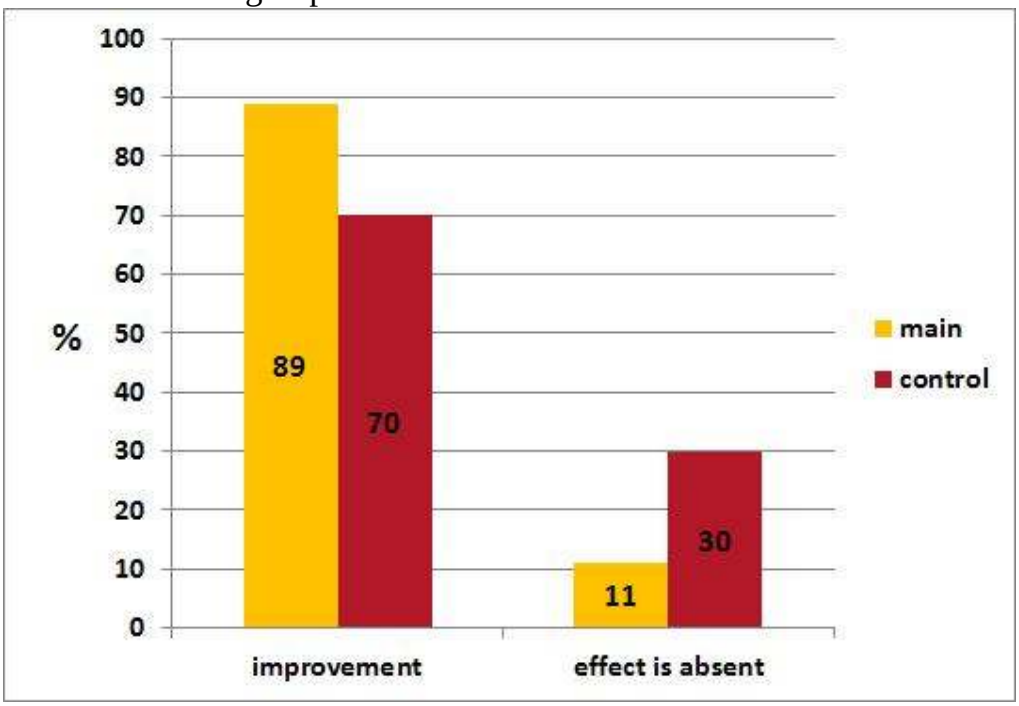

Fig. 2. Dynamics of restoring neurological functions of patients with ADEM in the main clinical group as a result of treatment.

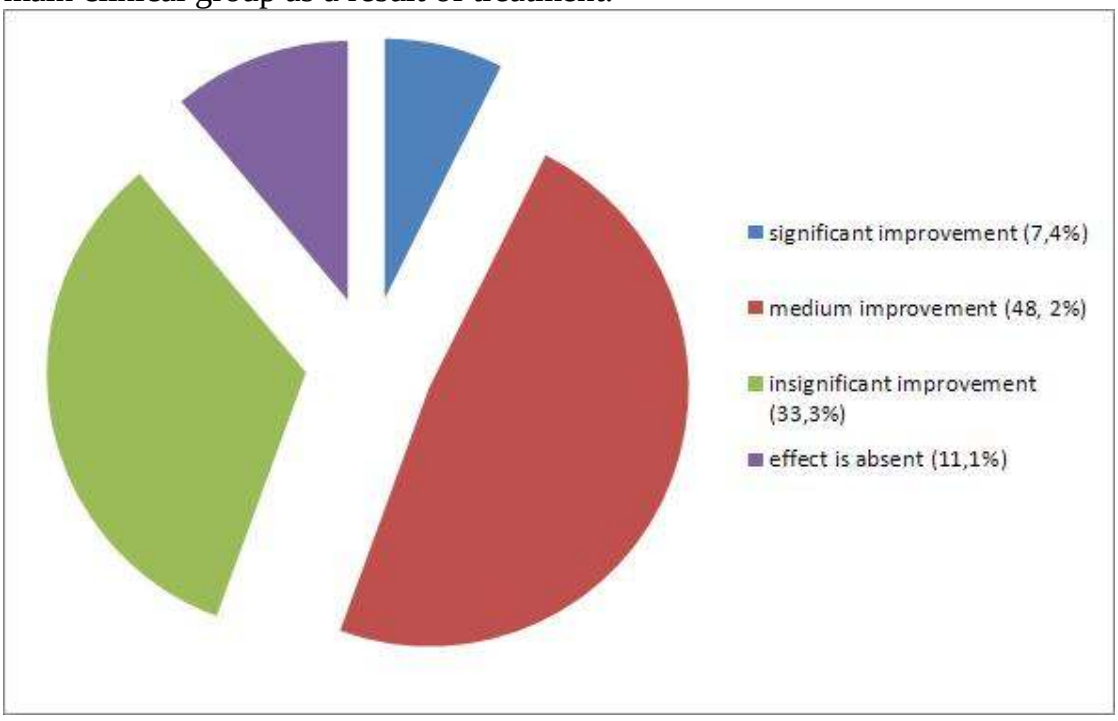

Fig. 3. Dynamics of changes in neurological status of patients with ADEM according to the EDSS scale over a 24-month observation period.

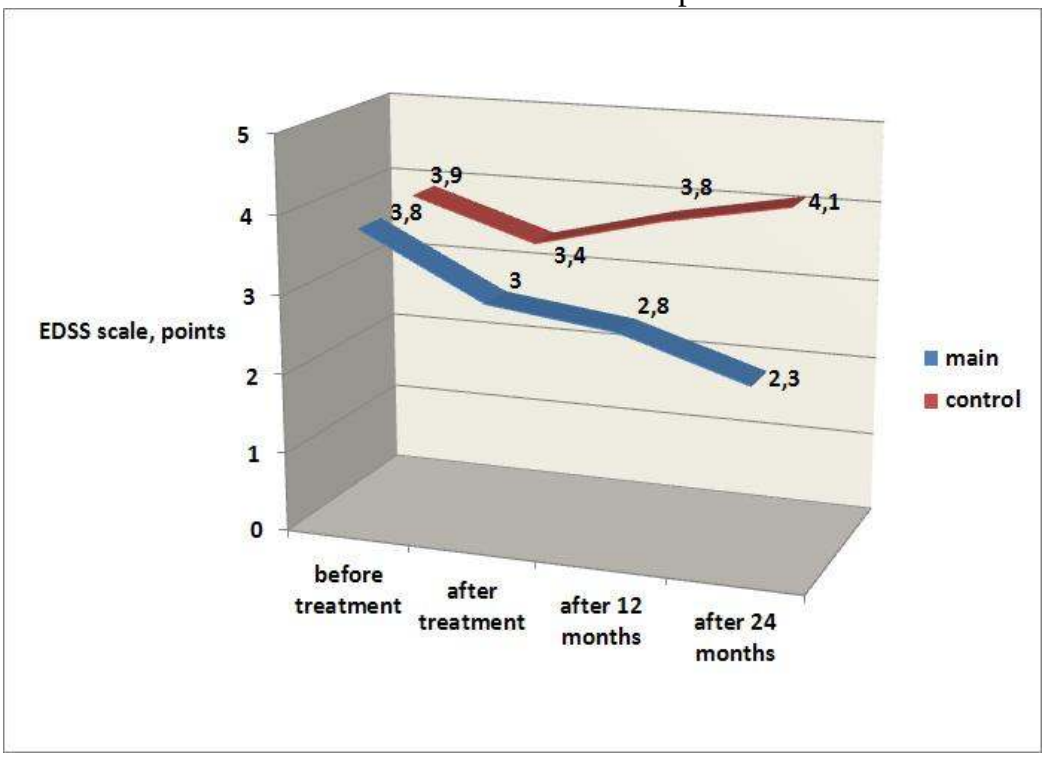

Fig. 4. MRI data of the patient G., 37 years old. Multiple, large foci of high intensity of signal (of different sizes) in the T2 mode, located in the frontal, temporal and parietal lobes of both hemispheres (dated 21.01.2011).

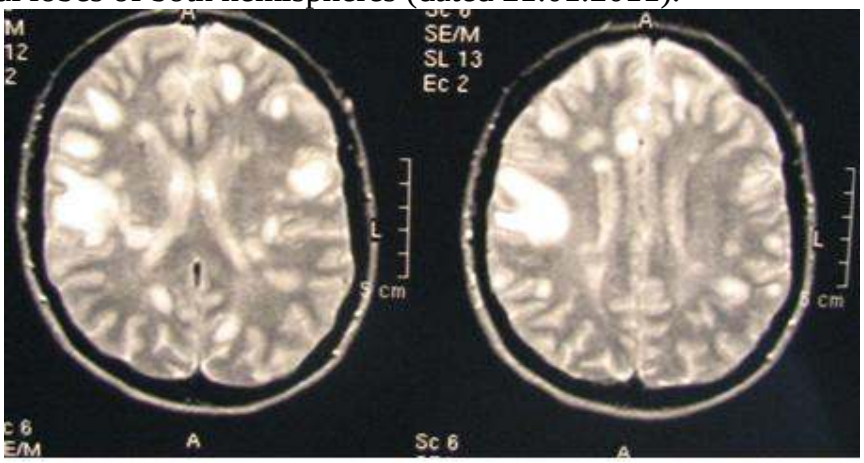

Fig. 5. MRI data of the patient D., 37 years old. Multiple, large foci of high intensity of signal (of different sizes) in the T2 mode, located in the frontal, temporal and parietal lobes of both hemispheres (dated 21/03/2011).

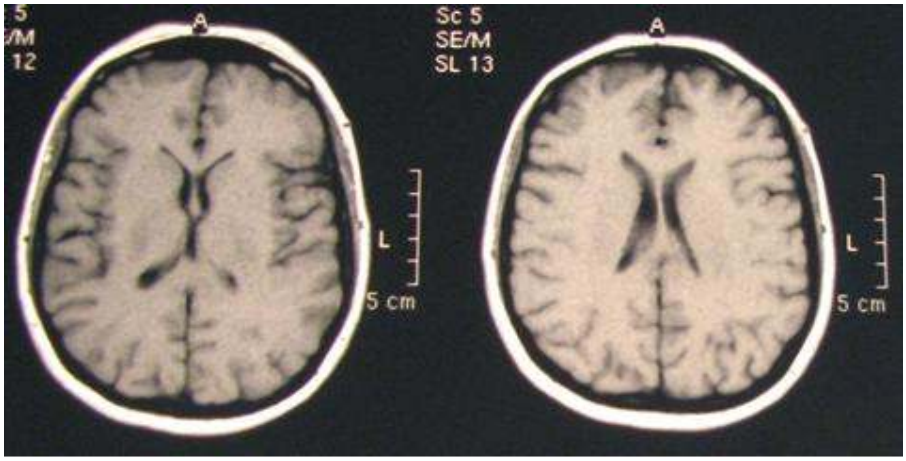

Conclusion:

The performed investigations prove the positive therapeutic efficacy of intravenous administration of human normal immunoglobulin in the treatment of patients with acute disseminated encephalomyelitis. Immunoglobulin administration contributes to the reduction of clinical manifestations of the disease by decreasing the level of neurologic deficit. Monthly administration of human normal immunoglobulin is of great prognostic importance, preventing the multi-phase course of the acute disseminated encephalomyelitis.

References:

1. Gard RK. **Acute disseminated encephalomyelitis.** *Postgraduate Medical Journal*. 2003, **79**: 11 – 17.
2. Dale RC, Sousa C, Chong WK. **Acute disseminated encephalomyelitis, multiphasic disseminated encephalomyelitis and multiple sclerosis in children.** *Brain*. 2000, **123**: 2407 – 2224.
3. Murthy J M. **Acute disseminated encephalomyelitis.** *Neurol. India.* 2002, **50**: 238-243.
4. Hollinger P, Sturzenegger M, Mathis J. **Acute disseminated encephalomyelitis in adults: a reappraisal of clinical, CSF, EEG, and MRI findings.** *J. Neurol.* 2002, **249**: 320 – 329.
5. Bahadori HR, Williams VC, Turner RP. **Acute disseminated encephalomyelitis following infectious mononucleosis**. *J. Child Neurol.* 2007, **22 (3):** 324 – 328.
6. Boz C, Veloiglu S, Ozmenoglu M. **Acute disseminated encephalomyelitis after bee sting.** *Neurol. Sci.* 2003, **23**: 313-315.

7. Chandra SR, Kalpana D, Anilkumar TV. **Acute disseminated encephalomyelitis following leptospirosis.** *J. Assoc. Physicians India.* 2004, **52**: 327 – 329.
8. Ciftci E, Ince E., Belgemen T. **Acute disseminated encephalomyelitis associated with Epstein-Barr virus infection.** *J. Ancara medical school*. 2003, **25 (3):** 149 – 154.
9. Ravaglia S. **Severe steroid-resisnant post-infectious encephalomyelitis: general features and effects of IVIg**. *J. Neurol.* 2007, **254 (11):** 1518 – 1523.
10. Shahar E. **Outcome of severe encephalomyelitis in children: effect of high-dose methylprednisolone and immunoglobulin**. *J. Child Neurol.* 2002, **17:** 810 – 814.
11. Sonneville R. **Acute disseminated encephalomyelitisin the intensive careunit: clinical features and outcome of 20 adults.** *Intensive Care Med.* 2008, **24 (3):** 528 – 532.
12. Tenembaum S. **Acute disseminated encephalomyelitis.** *Neurology*. 2007, **68:** 23 – 26.
13. Van Dam NC, Eron Syed S, Ostrander M. **Severe postvaccinal encephalitis with ADEM: recovery with early intravenous Ig, high-dose steroids and Vaccina Ig**. *Clinical infectious disease*. 2009. **48:** 47 – 49.
14. Fu DC, Montgomery JR. **High-dose, rapid-infusion IVIG in postvaccination acute disseminated encephalomyelitis**. *Neurology.* 2008, **71:** 294 – 295.
15. Kotlus BS, Slavin ML, Guthrie D. **Ophthalmologic manifestations in pediatric patients with acute disseminated encephalomyelitis**. *J AAPOS*. 2005, **9 (2):** 179 – 183.
16. Meca-Lallana JE. **Plasmaferesis: its use in multiple sclerosis and other demyelinating processes of the central nervous system. An oaservational study**. *Rev. Neurol.* 2003, **37:** 917 – 926.
17. Ohya T, Nagamitsu S, Yamashita Y. **Serial magnetic resonance imaging and single photon emission computed tomography study of acute disseminated encephalomyelitis patient after Japanese encephalitis vaccination.** *Kurume Med. J.* 2007, **54(3-4):** 95 – 99.
18. Sunnerhagen KS, Johansson K, Ekholm S. **Rehabilitation problems after acute disseminated encephalomyelitis**. *J. Rehabilitation Medicine.* 2003, **35:** 20 – 25.
19. Varilek BZ, Eron Syed S, Ostrander M. **Acute disseminated encephalomyelitis following pleural empyema owing to Boerhaave's syndrome.** *J. Child Neurol.* 2004, **19 (3):** 224 – 227.
20. Nishicava M, Ichiama T. **Intravenous immunoglobulin therapy in acute disseminated encephalomyelitis.** *Pediatr. Neurol.* 1999, **21(2):** 583 – 586.

21. Pittock SJ. **Rapid clinical and CSF response to intravenous gamma globulin in acute disseminated encephalomyelitis.** *Eur. J. neurology*. 2001, **8:**723 – 725.
22. Shiraiwa N, Yoshizawa T, Ohkoshi N. **A case of acute disseminated encephalomyelitis (ADEM) associated with peripheralneuropathy**. *Rinsho Shinkeigaku*. 2007, **47 (4):** 169 – 172.
23. Straussberg R. **Improvement of atypical acute disseminated encephalomyelitis with steroids and intravenous immunoglobulins**. *Pediatric Neurology*. 2001, **24:** 139 – 143.
24. Unay B. **Intravenous immunoglobulin therapy in acute disseminated encephalomyelitis associated with hepatitis A infection**. *Pediatr. Int.* 2004, **46 (2):** 171 – 173.
25. Azulay JP, Verschueren A, Attarian S. **Guillain-Barre syndrome and its frontiers.** *Rev. Neurol*. 2002, **158 (123):** 21 – 26.
26. Barohn RJ, Saperstein DS. **Guillain-Barre syndrome and chronic inflammatory demyelinating polyneuropathy.** *Semin. Neurol.* 1998, **18 (1):** 49 – 61.
27. De Grandis E, De Negri E, Montaldi L. **Intravenous immunoglobulins as therapeutic option in the treatment of multiple sclerosis.** *J. Neurol*. 2006, **253:** 50 – 58.
28. Gorson KC, Allam G, Ropper AH. **Chronic inflammatory demyelinating polyneuropathy: clinical features and response to treatment in 67 consecutive patients with and without a monoclonal gammopathy**. *Neurology*. 1997, **48 (2):** 321 – 328.
29. Smith-Jensen T, Burgoon, M, Anthony G, et al. **Comparison of IgG heavy chain sequences in MS and SSPE brain reveal an antigen-driven response.** *Neurology*. 2000, **54:** 1227 – 1232.
30. Takigawa T, Yasuda H, Terada M. **The sera from GM1 ganglioside antibody positive patients with Guillain-Barre syndrome or chronic inflammatory demyelinating polyneuropathy blocks Na+ currents in rat single myelinated nerve fibers.** *Intern. Med.* 2000, **39 (2):** 123 – 127.
31. Villa AM, Molina H, Sanz OP. **Chronic inflammatory demyelinating polyneuropathy. Findings in 30 patients.** *Medicina.* 1999, **59 (6):** 721 – 726.
32. Vital C, Vital A, Gbikpi-Benissan G. **Postvaccinal inflammatory neuropathy: peripheral nerve biopsy in 3 cases.** J. *Peripher. Nerv. Syst.* 2002, **7 (3):** 163 – 167.
33. Giovanni SR, Ceroni PM**. Severe steroid-resistant post-infectious encephalomyelitis. General features and effects of IVIg.** *Neurol.* 2007, **254:** 1518 – 1523.
34. Marchioni E, Marinou-Aktipi K, Uggetti C. **Efficacy of intravenous immunoglobulin treatment in adult patients with steroid-resistant**

UNDER PEER REVIEW

monophasic or recurrent acute disseminated encephalomyelitis. *J. Neurol*. 2002, **249 (1):** 100 – 104.

35. Laderman M, Gabelin P, Lafrenz M. **Acute disseminated encephalomyeltis malaria caused by Varicella Zoster Virus reactivation**. *Amer. J. Trop. Med. Hyg*. 2005, **72 (4):** 478 – 480.
36. Lin CH, Jeng JS, Yip PK. **Plasmapheresis in acute disseminated encephalomyelitis**. *J. Clin. Apher.* 2004, **19 (3):** 154 – 159.
37. Ramachandran NR, Parameswaran MG. **Acute disseminated encephalomyelitis treated with plasmapheresis.** *Singapore Med J.* 2005, **46 (10):** 561 – 563.
38. Ramachandran NR. **Plasmapheresis in childhood acute disseminated encephalomyelitis**. *Indian Pediatr*. 2005, **42(5):** 479 – 482.
39. Refai D. **Decompressive hemicraniectomy for acute disseminated encephalomyelitis**. *Neurosurgery*. 2005, **56(4):** 870 – 872.
40. Kurtzke JF. **Rating neurological impairment in multiple sclerosis: an expanded disability staty scale (EDSS).** *Neurology*. 1983, **3:**1444 – 1452.